

PATIENT

Ryker Rescue

PRESENTING CLINICAL SIGNS

History: Heartworm +, finished treatment 1 month ago, 3/6 murmur, exercise intolerance per foster parent Doxycycline, Vetmedin 0.625 BID, Lasix 2.5 BID

SPECIES

Canine

ELECTROCARDIOGRAPHIC FINDINGS *Note: Single lead ECGs are evaluated as a rhythm strip. Morphology/MEA cannot be definitively commented on.

BREED

Yorkie Mix

A single lead ECG is available from an AliveCor monitor; 50mm/s, 20mm/mV. Baseline interference throughout. The average heart rate is 100bpm (range 63-120bpm). The rhythm is sinus in origin, although p waves are difficult to visualize. The QRS morphology is positive with normal dimension. No ectopic beats, pauses or other dysrhythmias observed.

ECG diagnosis: Normal sinus rhythm with respiratory variation.

SEX

Male Neutered

INTERPRETATION OF THE FINDINGS & FURTHER RECOMMENDATIONS

Normal ECG with no evidence of dysrhythmias or chamber enlargement patterns. If this does not match what was heard on exam (i.e. premature beats), a longer tracing or potentially a Holter monitor may be necessary.

AGE

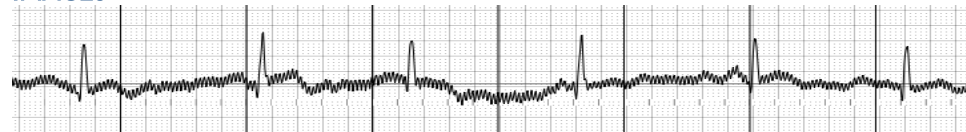
2018

No comment on the heartworm disease can be made from an ECG alone. Follow-up and treatment should be dictated by the echocardiogram results, clinical assessment, etc.

WEIGHT

5 lbs

IMAGES



INTERPRETED BY

Maggie Machen Lamy,
DVM, DACVIM
(Cardiology)

The information and recommendations provided are based on the images presented by the referring veterinarian. No evaluation can be communicated regarding pathology that was not visible in the image/video clips provided.

IMAGING PERFORMED BY

Rebekah Jakum, CVT
ARDMS/RVT

Thank you for this referral. If the clinical or image interpretation does not parallel your findings or if I can be of any further assistance please contact me.

Maggie Machen Lamy, DVM
Diplomate of the American College of Veterinary Internal Medicine (Cardiology)
info@sonopath.com

HOSPITAL NAME

New Britain VC

REFERRING VET

Dr. Bandekar

INVOICE

23469

DATE

4/4/22